# REUNIÃO BIBLIOGRÁFICA




## Virtual Hysterosalpingography: A New Multidetector CT Technique for Evaluating the Female Reproductive System[1]

*Patricia M. Carrascosa, MD, PhD • Carlos Capuñay, MD • Javier Vallejos, MD • Elba Beatriz Martín López, MD • Mariano Baronio, MD • Jorge Manuel Carrascosa, MD*

**Micael Sousa Mendes**
**Moderação: Drº José Ilharco**

# ESTRUTURA DO ARTIGO

- Introdução
- Técnica da HSG Virtual
- Ferramentas pós-processamento
- Complicações
- Desconforto do doente
- Exposição à radiação
- Variações anatómicas normais
- Achados patológicos do colo uterino
- Achados patológicos do útero
- Anormalidades das trompas uterinas
- Achados acidentais extra-uterinos
- Conclusões

# INTRODUÇÃO

- Avanços da medicina reprodutiva → necessidade de novos métodos de imagem

- HSG virtual = HSG convencional + TAC multicorte

- HSG convencional

Técnicas

| Indicações | Complicações |
| --- | --- |
| -Infertilidade<br>- Abortos espontâneos recorrentes<br>- Avaliação pré-operatória de miomectomia<br>- Avaliação pós-cirúrgica de laqueação tubar | - Hemorragia<br>- Infecção |

- TAC multicorte
  - revolucionou o estudo do coração, cólon e vias áreas
  - imagens 2D, reconstruções 3D e endoscopia virtual
  - informação adicional de outras estruturas pélvicas adjacentes

# TÉCNICA DA HSG VIRTUAL

- AB profiláctica

- 7-10º dia do ciclo menstrual

**Contra - Indicações**

-Gravidez
- Infecção pélvica activa

- Posição ginecológica; assepsia do períneo e colo (iodopovidona); cânula 10 F

- 2,5 ml de iobitrol diluído em 12,5 ml de solução salina (injector)

- Aparelho TAC 64 cortes (inicio da aquisição aos 45 seg)

| Parâmetros técnicos | |
|---|---|
| Detector collimation | 64 x 0,625 mm |
| Section thickness | 0,9 mm |
| Reconstruction interval | 0,45 mm |
| Scanning time | 3-4 seg |

Automatic modulation of the tube current (range, 120–250 mAs) is used to allow radiation dose saving in accordance with the patient's size along the z-axis. The acquired image

# FERRAMENTAS PÓS-PROCESSAMENTO

- Reformatações multiplanares
    - Imagem multiplanar curvilinea

- MIP ("Maximum Intensity Projection")
    - excelente detalhe anatómico (p.e. trompas)

- Volume rendering
    - 3D; útil para detectar estenoses, irregularidade da parede, pólipos e hidrosalpinge

- Endoscopia Virtual
    - esclarecimento de achados duvidosos

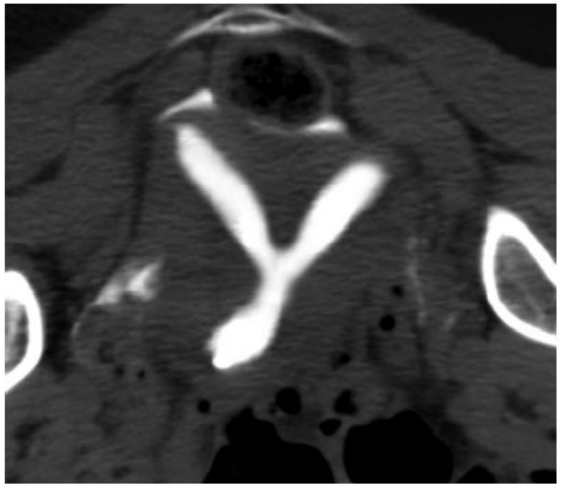

**Figure 1.** Curved multiplanar image from virtual hysterosalpingography depicts a septate uterus. Curved multiplanar reconstructions allow simultaneous evaluation of the uterine cavity and wall.

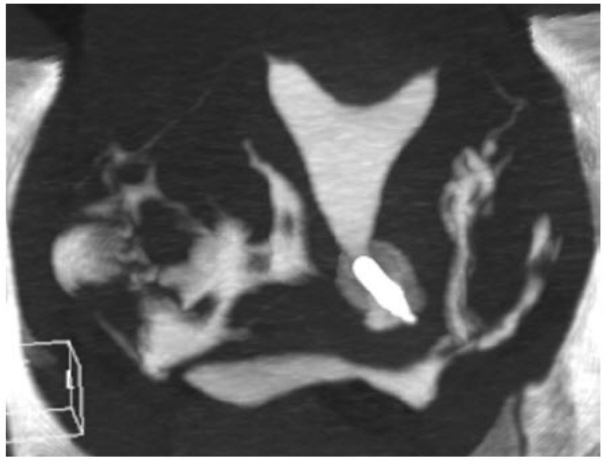

**Figure 2.** MIP image from virtual hysterosalpingography provides excellent depiction of the fallopian tubes, which appear patent, with an adequate amount of contrast material spilling into the peritoneal cavity.

**Figure 3.** Volume-rendered image from virtual hysterosalpingography shows the normal appearances of the cervix, uterus, and fallopian tubes.

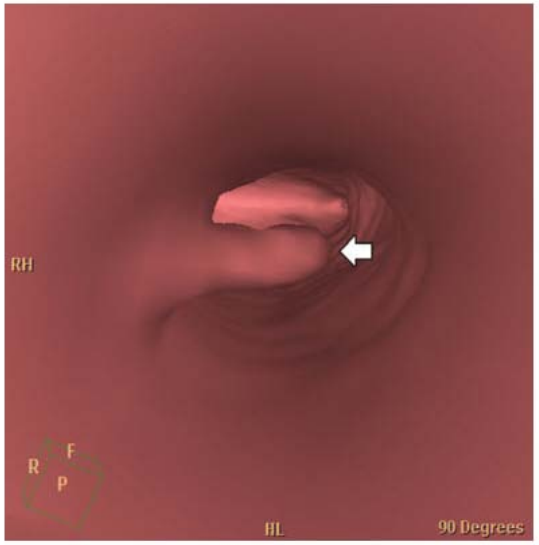


**Figure 4.** Virtual endoscopic image from virtual hysterosalpingography shows an endometrial polyp that protrudes from the lateral uterine wall (arrow).

## COMPLICAÇÕES

- risco extremamente baixo (Ø “clamping” do colo, tracção do colo)
- ↓ risco de reacções vaso-vagais (exame indolor)

## DESCONFORTO DO DOENTE

- HSG convencional > Histerosonografia ou Histeroscopia
- Ø necessidade de “clamping” ou tracção do colo
- Ø necessidade de posicionamentos (filme 3 → decúbito lateral dto)

➡ menos doloroso, mais confortável e mais bem tolerada

# EXPOSIÇÃO À RADIAÇÃO

- PROBLEMA!!! → irradiação das gónadas em ♀ em idade reprodutiva

- HSG convencional: 1mSv (extremamente díficil conseguir na prática)

practice (19). The estimated radiation dose for virtual hysterosalpingography also may be relatively low; at our center, it is even lower than that for conventional hysterosalpingography (20). Many

methods is automatic tube current modulation along the z-axis. In our series of more than 1000

along the z-axis. In our series of more than 1000 patients, the mean effective radiation dose for virtual hysterosalpingography performed with this dose reduction method was 2.6 mSv (9).

- técnicos e médicos não são expostos à radiação

# VARIANTES ANATÓMICAS NORMAIS

## HIPERPLASIA DAS GLÂNDULAS DO COLO UTERINO

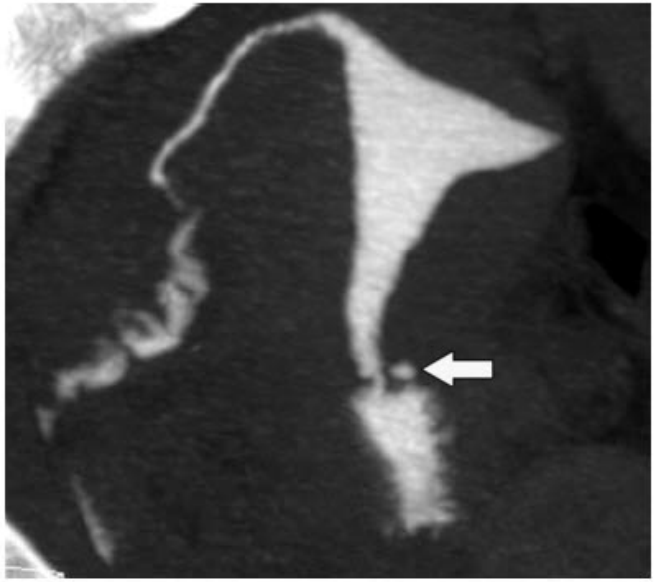

Figure 6. MIP image from virtual hysterosalpingography in a 34-year-old woman with a history of infertility shows a small diverticulum-like outpouching (arrow) in the left lateral wall of the cervical canal. This incidental finding represents a normal cervical gland.

- protrusão para fora do contorno do colo com um aspecto tubular ou sacular
- glândulas endocervicais normais, mas mais proeminentes preenchidas por produto de contraste

# VARIANTES ANATÓMICAS NORMAIS

## PREGAS UTERINAS

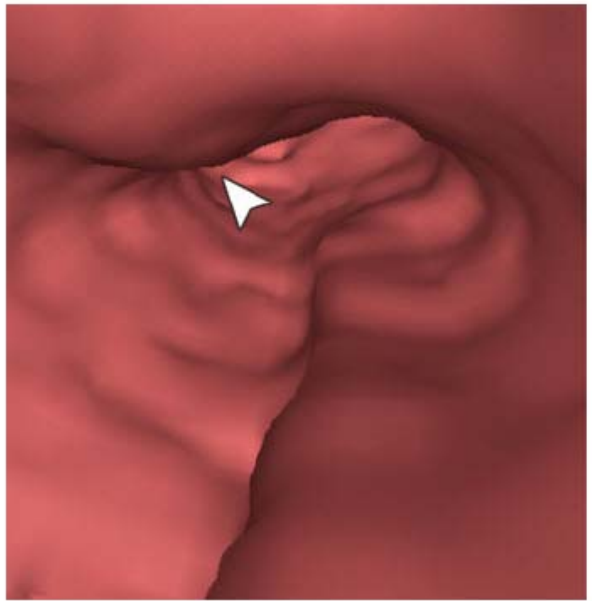

Figure 7. Myometrial folds. Virtual endoscopic view from multidetector CT hysterosalpingography in a 38-year-old patient with a history of secondary infertility shows multiple linear structures that parallel the long axis of the cervix (arrowhead). This is a normal appearance of the myometrium.

- pregas longitudinais distribuídas paralelamente ao eixo longo do corpo uterino

- não associadas a patologia

  → remanescentes dos ductos de Muller

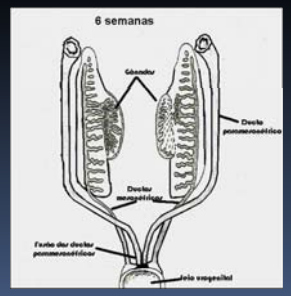

# VARIANTES ANATÓMICAS NORMAIS

## ESPASMOS TUBARES

- defeitos de preenchimento de lineares que parecem separar os cornos uterinos da cavidade uterina

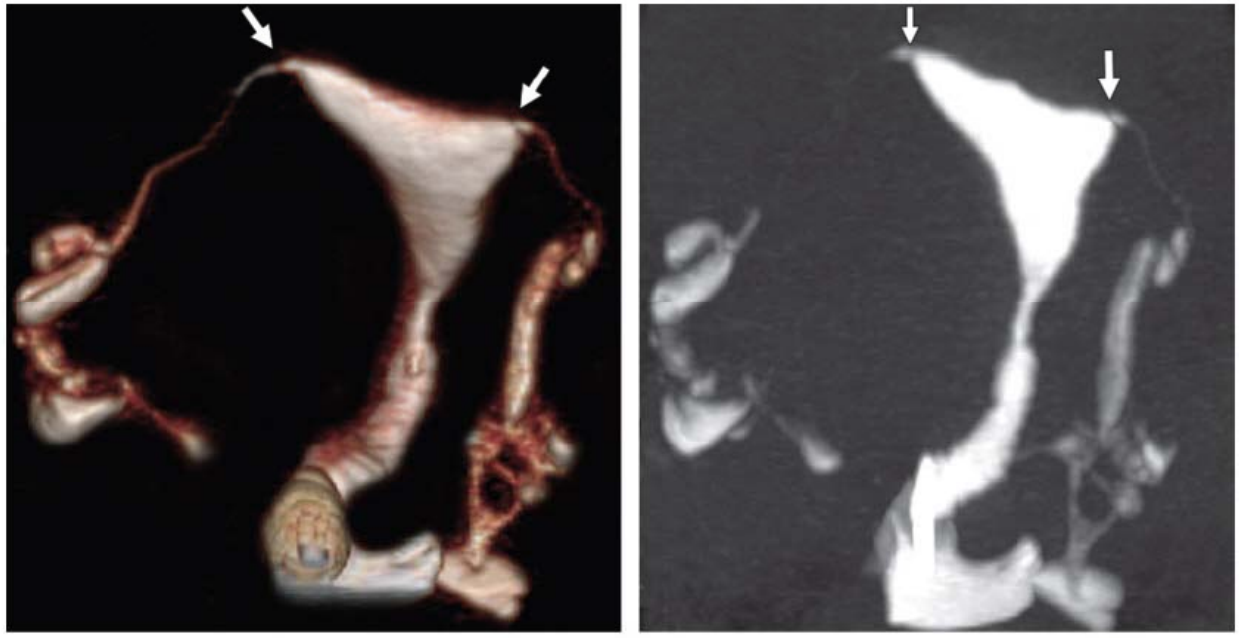

a. b.

Figure 8. Muscle contractions mimicking cornual disruption in a 41-year-old woman with primary infertility. Volume-rendered (a) and MIP (b) images from virtual hysterosalpingography show symmetric linear defects (arrows) at the cornual-tubal junctions, findings indicative of normal muscle contractions.

# ACHADOS PATOLÓGICOS DO COLO UTERINO

- CALIBRE
  - Dilatação
  - Estreitamento / Estenose
    - Variante do normal
    - Achado patológico
      - adesões pós-cirúrgicas
      - trauma instrumental
      - leiomioma do colo uterino
- DEFEITOS DE REPLECÇÃO
  - pólipos
  - sinéquias
  - remanescentes congénitos
  - miomas submucsoso

cosal myomas. Polyps occur infrequently in this location, but they are easily detected at virtual hysterosalpingography. Findings on the initial axial images viewed with soft-tissue window settings may be verified subsequently on virtual endoscopic views (Fig 12). Cervical synechiae,

# ACHADOS PATOLÓGICOS DO ÚTERO

**Forma**
- Anomalias congénitas
- Anomalias adquiridas

**Defeitos de replecção**
- Pólipos endometriais
- Miomas submucosos

**Anormalidades de parede uterina**
- Leiomiomas
- Adenomiose
- Alterações pós-cirúrgicas

# ACHADOS PATOLÓGICOS DO ÚTERO

## ANOMALIAS CONGÉNITAS DA FORMA

- útero arqueado
- útero septado
- útero unicórneo
- útero bicórneo

**Figure 14.** Unicornuate uterus in a 29-year-old woman with primary infertility. MIP image from virtual hysterosalpingography shows an asymmetric and laterally displaced uterus that lacks the customary pear shape.

# -útero bicórneo Vs útero septado

a bicornuate uterus. However, in most cases, the two anomalies have a similar appearance at hysterosalpingography, and the hysterosalpingographic findings must be correlated with US or MR imaging findings for accurate differentiation (4).

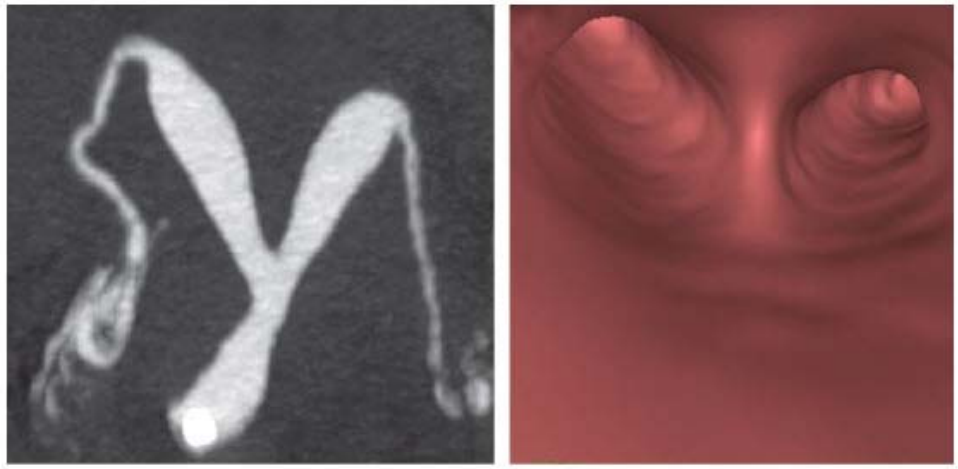

a. b.

**Figure 16.** Septate uterus in a 32-year-old woman with a history of recurrent abortions. **(a)** MIP view shows an incomplete uterine septum. **(b)** Virtual endoscopic view shows the septum and both cornua.

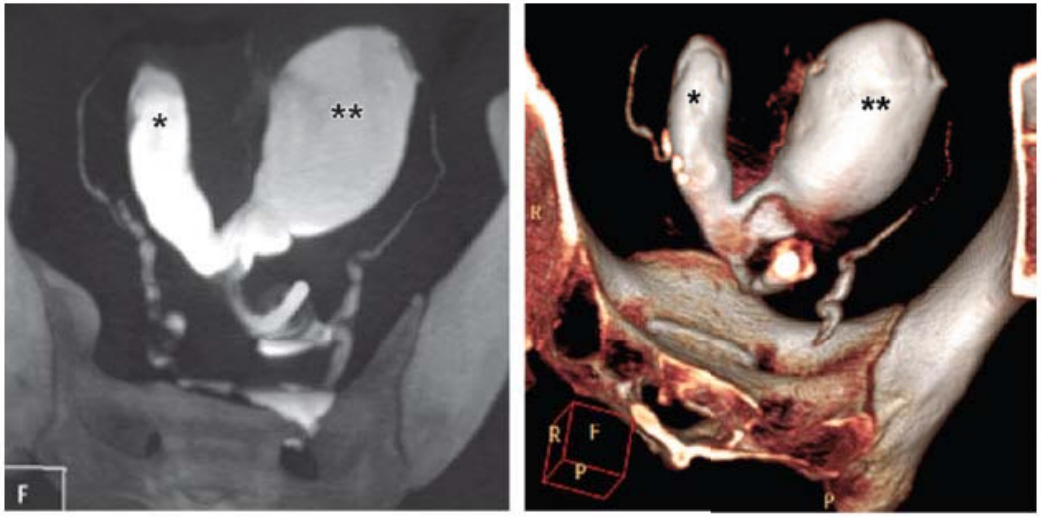


a. b.

**Figure 15.** Bicornuate uterus in a 37-year-old patient with primary infertility. MIP **(a)** and volume-rendered **(b)** images from virtual hysterosalpingography show a uterus with a normal right cornu (*) and a dilated left cornu (**).

An advantage of virtual hysterosalpingography is its capability for evaluating the uterine wall and delineating the external uterine contour. With this capability, virtual hysterosalpingography may be more useful than other imaging techniques for achieving a precise diagnosis of congenital anomalies in a single examination.

# ACHADOS PATOLÓGICOS DO ÚTERO

## DEFEITOS DE REPLECÇÃO

### PÓLIPOS ENDOMETRIAIS

- HSG convencional - distinção díficil com miomas submucosos
  - pequenas dimensões → passam despercebidos

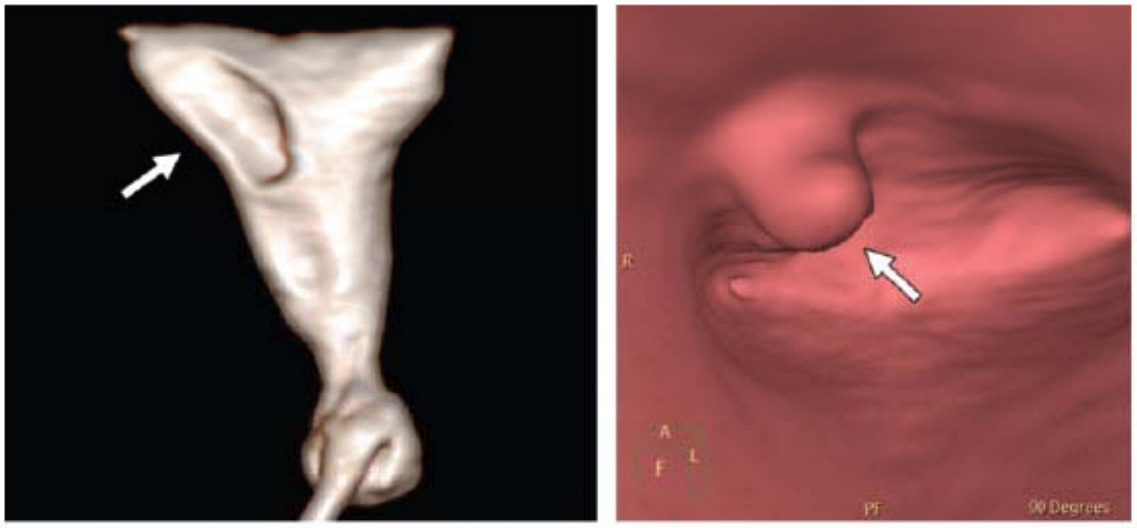


**Figure 17.** Endometrial polyp. **(a)** Volume-rendered image shows a filling defect in the anterior wall of the uterine cavity (arrow). **(b)** Virtual endoscopic view shows an elevated lesion (arrow) that represents a polyp.

- HSG virtual
  - dg preciso destas lesões
  - detecta pólipos de dimensões reduzidas

# ACHADOS PATOLÓGICOS DO ÚTERO

## DEFEITOS DE REPLECÇÃO

### MIOMAS SUBMUCOSOS

- leiomiomas submucosos → abortos recorrentes, menorragias e infertilidade
- HSG convencional – defeitos de preenchimento que distorcem cavidade uterina
- HSG virtual - formações com atenuação > ou < que o miométrio normal

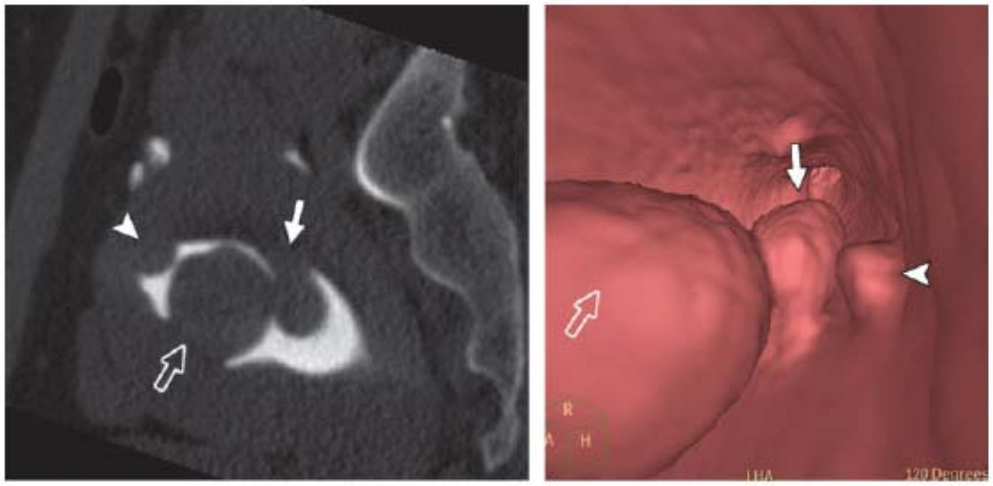

a. b.

Figure 18. Submucosal myomas in a 43-year-old patient with a history of worsening metrorrhagia over 1 year. (a) Sagittal multiplanar reconstruction shows the uterus distended by contrast material, with multiple filling defects in the anteroinferior (open arrow), posterosuperior (solid arrow), and anterior (arrowhead) aspects of the wall, findings suggestive of submucosal leiomyomas. (b) Virtual endoscopic view shows the corresponding lesions protruding into the uterine cavity (arrows and arrowhead).

- <u>HSG virtual</u>
- formações com atenuação > ou < que o miométrio normal
- facilmente diferencia os miomas submucosos de outras causa de defeitos de replecção

# ACHADOS PATOLÓGICOS DO ÚTERO

## DEFEITOS DE REPLECÇÃO

### SINÉQUIAS

- aderências uterinas (curetagem endometrial ++; inf endometriais)
- síndrome de Asherman (múltiplas sinéquias e infertilidade)

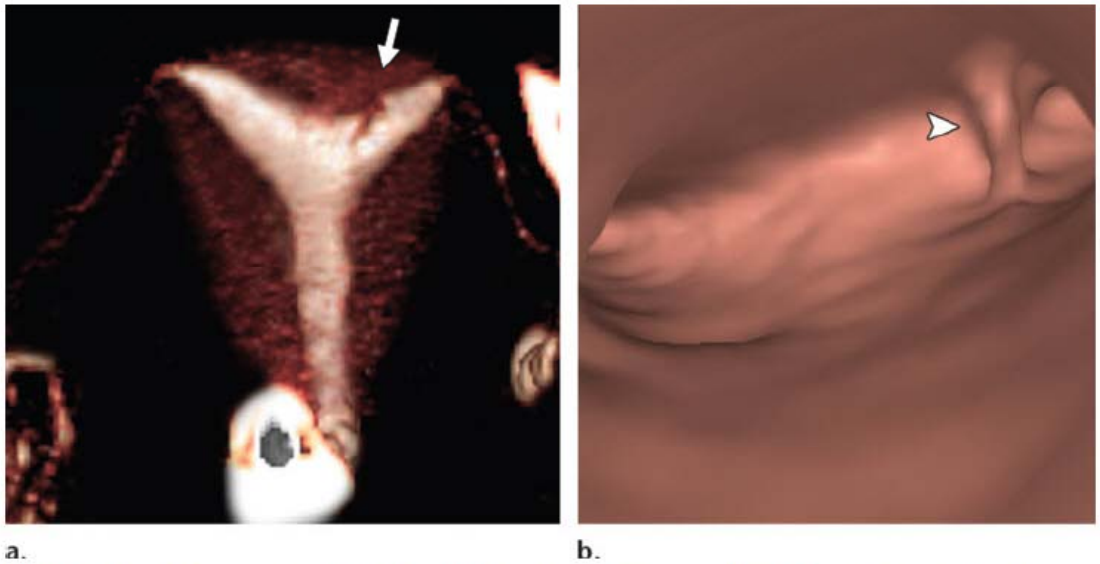


Figure 19. Uterine synechiae at virtual hysterosalpingography. (a) Volume-rendered image shows a linear defect (arrow) that extends from the uterine fundus to the body, a finding suggestive of a synechia. (b) Virtual endoscopic view shows extension of the adhesion to the region of the left cornu and fundus (arrowhead).

- HSG virtual
- imagens lineares e irregulares, com aspecto serpiginoso

# ACHADOS PATOLÓGICOS DO ÚTERO

## ANORMALIDADES DA PAREDE UTERINA

### LEIOMIOMAS

**Submucosos**

- Redução das dimensões da cavidade uterina ou distorção dos contornos desta
- Causa de infertilidade ao afectar patência da cavidade endometrial ou ao obstruir as trompas

**Intramurais**

- HSG convencional não consegue detectá-los
- Na HSG virtual são identificados como massas focais com atenuação diferente do miométrio normal

**Subserosos**

- HSG convencional não consegue detectá-los
- A HSG virtual consegue detectá-los porque alteram contorno externo do útero

# ACHADOS PATOLÓGICOS DO ÚTERO

## ANORMALIDADES DA PAREDE UTERINA

### LEIOMIOMAS

be missed at virtual hysterosalpingography. Post-treatment changes that may be depicted at virtual hysterosalpingography include fistulas that formed because of necrosis in endometrial lesions treated with embolization (Fig 20).

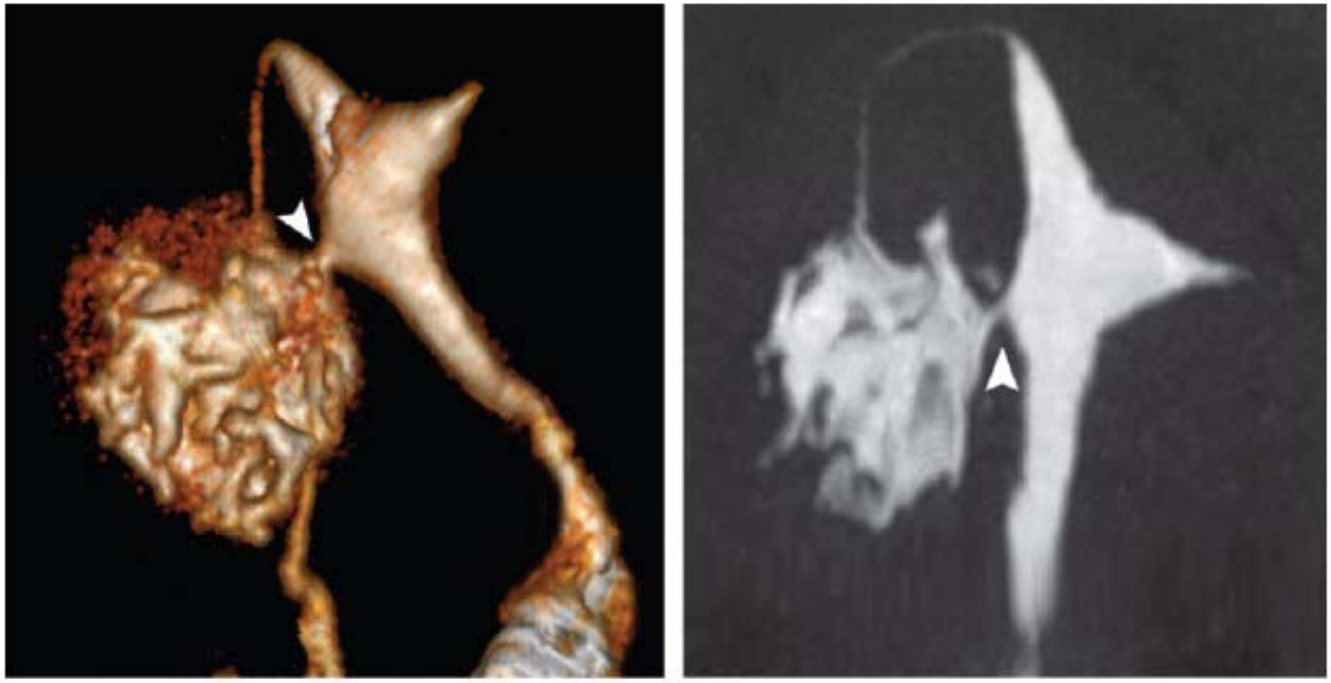

a. b.

**Figure 20.** Fistulation after embolization of an intramural myoma. Volume-rendered (**a**) and MIP (**b**) images from virtual hysterosalpingography show a connection (arrowhead) between the uterine cavity and the necrotic myoma.

# ACHADOS PATOLÓGICOS DO ÚTERO

## ANORMALIDADES DA PAREDE UTERINA

### ADENOMIOSE

- patologia em que as gls do endométrio se estendem para o interior do miométrio
- associada a infertilidade
- causa dor pélvica e hemorragia uterina anormal

**HSG virtual**

- imagem diverticular que se estende para o interior do miométrio
- achado pouco específico e apenas uma pequena percentagem representam de facto adenomiose

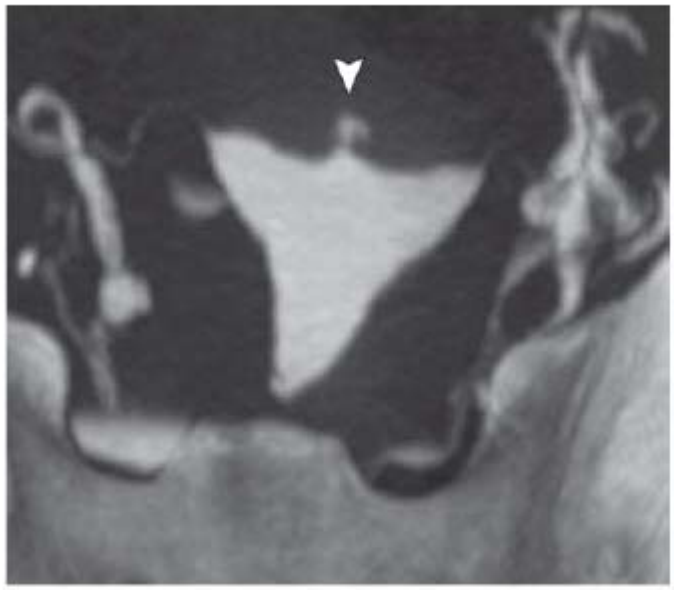

a.

**Figure 21.** Focal adenomyoma. (**a**, **b**) MIP (**a**) and volume-rendered (**b**) images from virtual hysterosalpingography show a small cavity in the fundus (arrowhead), a finding suggestive of a focal adenomyoma. (**c**) Virtual endoscopic view of the uterine interior in the region of the fundus shows the adenomyoma as a diverticulum-like outpouching (arrowhead).

**ADENOMIOSE FOCAL**

# ACHADOS PATOLÓGICOS DO ÚTERO

## ANORMALIDADES DA PAREDE UTERINA

**Figure 21.** Focal adenomyoma. (**a**, **b**) MIP (**a**) and volume-rendered (**b**) images from virtual hysterosalpingography show a small cavity in the fundus (arrowhead), a finding suggestive of a focal adenomyoma. (**c**) Virtual endoscopic view of the uterine interior in the region of the fundus shows the adenomyoma as a diverticulum-like outpouching (arrowhead).

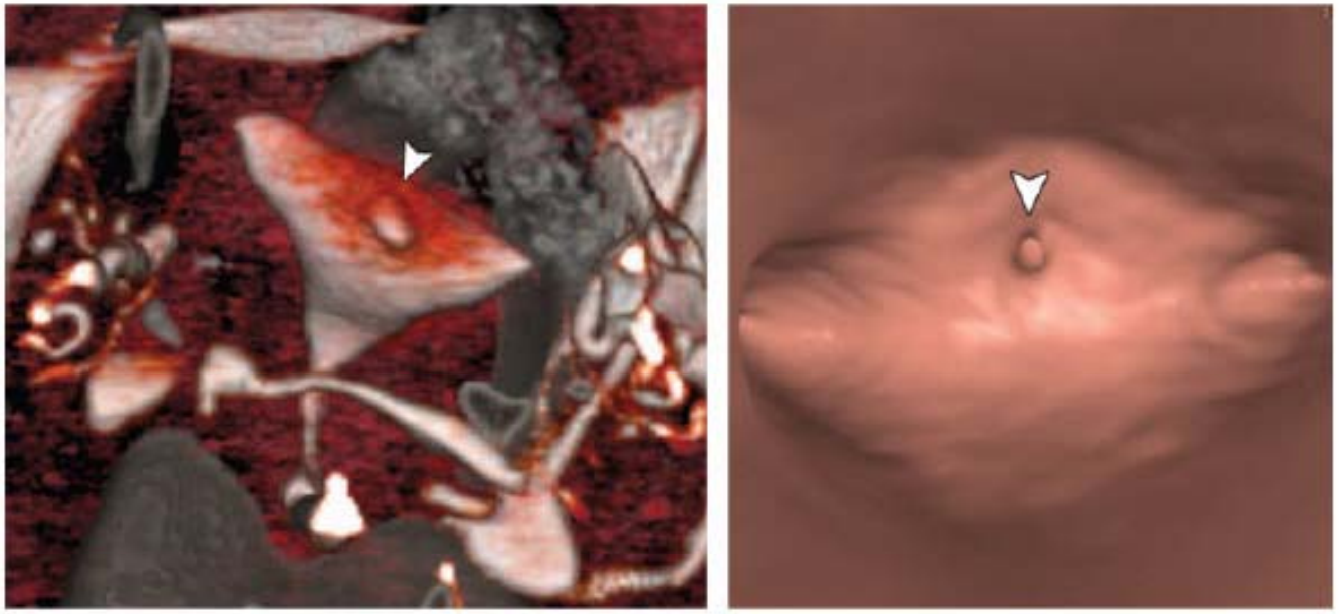

b. c.

# ACHADOS PATOLÓGICOS DO ÚTERO

## ANORMALIDADES DA PAREDE UTERINA

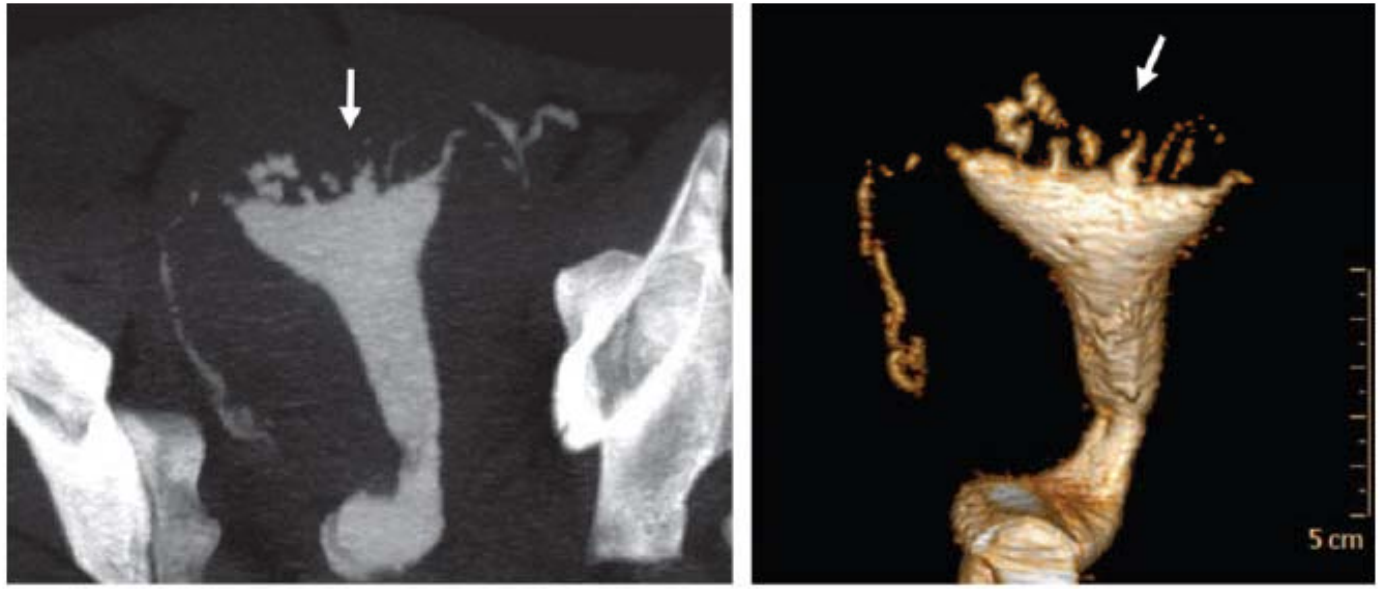


a. b.

Figure 22. Diffuse adenomyosis. MIP (a) and volume-rendered (b) images from virtual hysterosalpingography show multiple variable-sized branchlike cavities that extend into the uterine wall in the fundic region (arrow).

**ADENOMIOSE DIFUSA**

- "cavidades" de tamanhos variados, irregulares, com um aspecto ramificado e que se estendem da cavidade uterina para o miométrio

# ACHADOS PATOLÓGICOS DO ÚTERO

## ANORMALIDADES DA PAREDE UTERINA

### ALTERAÇÕES PÓS-CIRÚRGICAS

- HSG virtual permite visualizar alterações em ♀ que realizaram algum tipo de cirurgia (cesariana, miomectomia para tratamento de miomas submucosos)

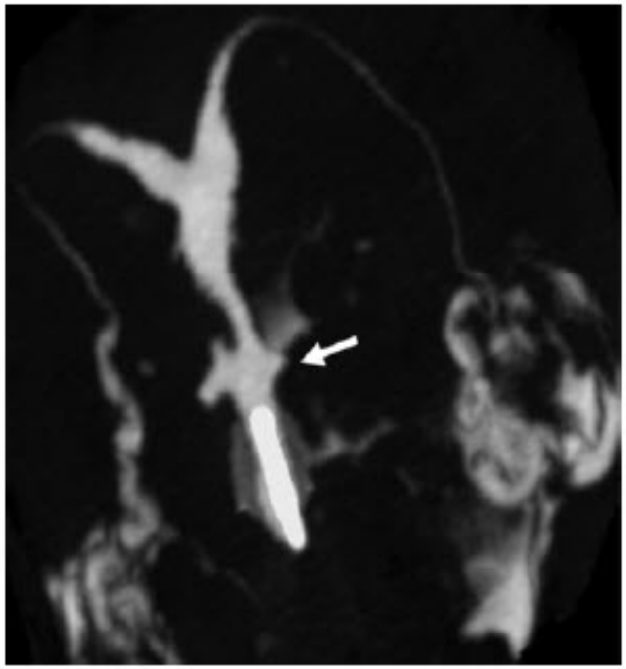

**Figure 23.** Postoperative adhesions from cesarean sections. MIP image from virtual hysterosalpingography in a 38-year-old woman with a history of two cesarean sections shows areas of irregularity and a wedge-shaped deformity (arrow) in the cervix.

CESARIANA → deformidade em forma de cunha ao nível do orifíco interno do colo uterino

# ACHADOS PATOLÓGICOS DO ÚTERO

## ANORMALIDADES DA PAREDE UTERINA

MÚLTIPLAS CESARIANAS → ruptura do tecido cicatricial pode levar à formação de uma fístula entre o útero e a cavidade pélvica

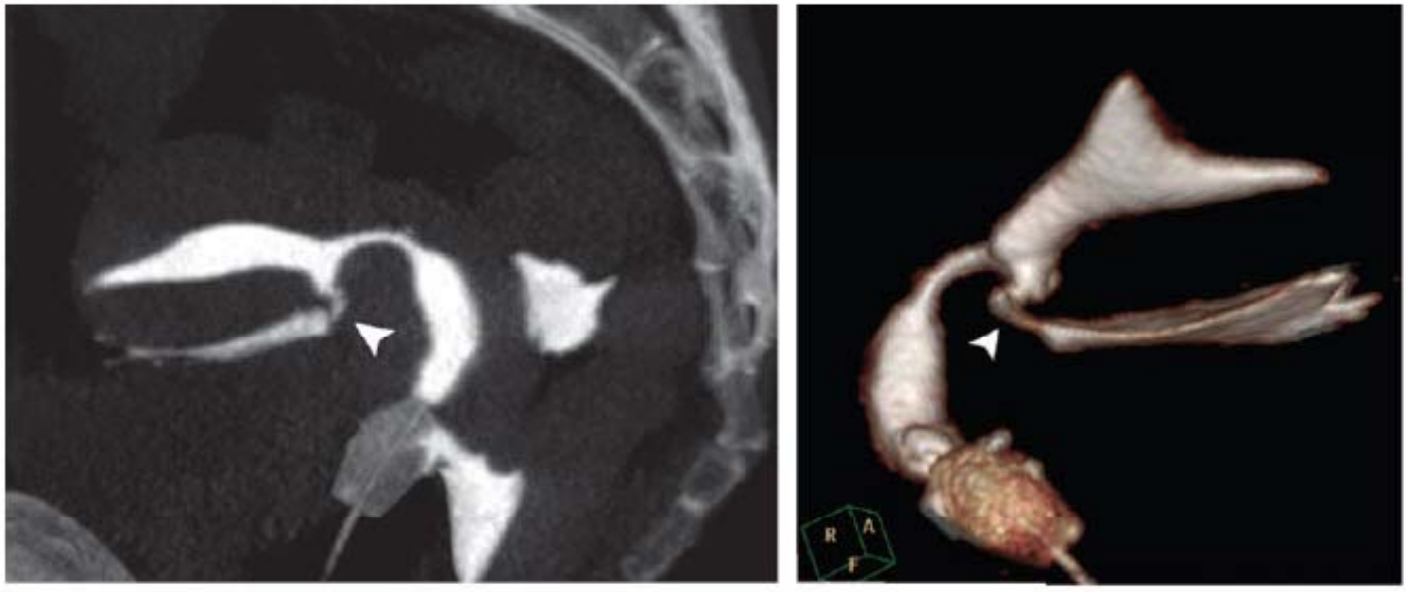


a. b.

**Figure 24.** Uterine fistula at virtual hysterosalpingography in a 37-year-old woman with a history of four cesarean sections, pelvic discomfort and frequent painful urination for 6 months, and severe menstrual pain. **(a)** Sagittal MIP image of the pelvis shows a linear defect (arrowhead) that extends outward from the uterus at the isthmus, a finding that represents a uterine fistula. **(b)** Coronal oblique volume-rendered image shows that the fistula (arrowhead) connects the uterus with free intraperitoneal fluid.

# ACHADOS PATOLÓGICOS DAS TROMPAS

- HSG virtual permite:
  - visualização do lúmen e parede das trompas
  - navegação endoscópica virtual pelo interior de trompas

spatial resolution constraints. Virtual hysterosalpingography performed with a 64-row multidetector CT scanner not only can depict the tubal lumen and tubal wall but also allows virtual endoscopic navigation within dilated tubes.

-Fácil detecção de oclusão ou estenose tubar

## OCLUSÃO TUBAR

- causa: infecção, pós-cirúrgica
- interrupção abrupta sem opacicação da porção + distal
- unilateral / bilateral
- se a oclusão ocorrer na porção ampular a trompa pode ficar dilatada e formar-se uma hidrossalpinge

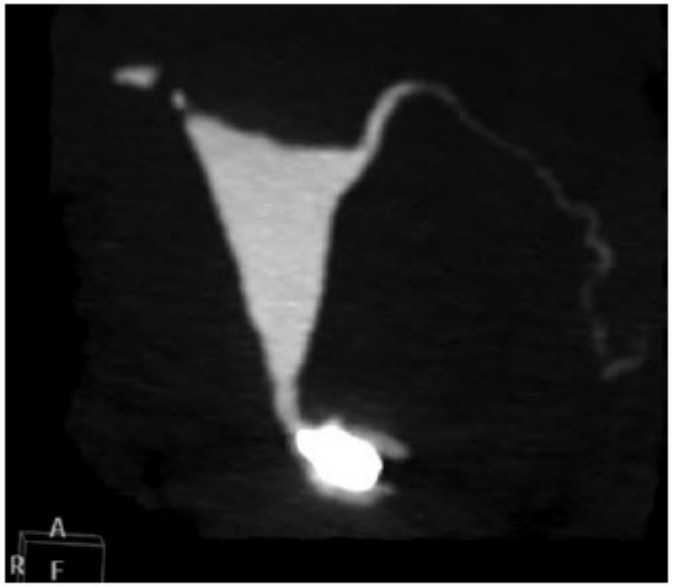

# ACHADOS PATOLÓGICOS DAS TROMPAS

## HIDROSSALPINGE

- causas: sequela de infecção, endometriose, cirurgia pélvica

- HSG virtual → consegue dar uma visão anatómica interna da trompa dilatada, semelhante à que se consegue com a Faloscopia, que é uma técnica micro-endoscópica que permite o exame directo das trompas

a. b.

**Figure 26.** Unilateral hydrosalpinx. Volume-rendered (**a**) and MIP (**b**) images from virtual hysterosalpingography show right ampullary dilatation, with no intraperitoneal spillage of contrast material.

# ACHADOS PATOLÓGICOS DAS TROMPAS

direct internal examination of the tubes. Like falloscopy, virtual endoscopic navigation during virtual hysterosalpingography allows the detection of adhesions within dilated fallopian tubes

a.

b.

c.

**Figure 27.** Ampullary tubal dilatation. **(a, b)** MIP **(a)** and volume-rendered **(b)** images from virtual hysterosalpingography demonstrate mild dilatation of the ampullary segments of both fallopian tubes, with intraperitoneal spillage of contrast material. **(c)** Virtual endoscopic image shows intratubal adhesions.

# ACHADOS ACIDENTAIS EXTRA-UTERINOS

- aquisição de imagens de toda a pélvis → vantagem de se poderem encontrar acidentalmente outros achados extra-uterinos

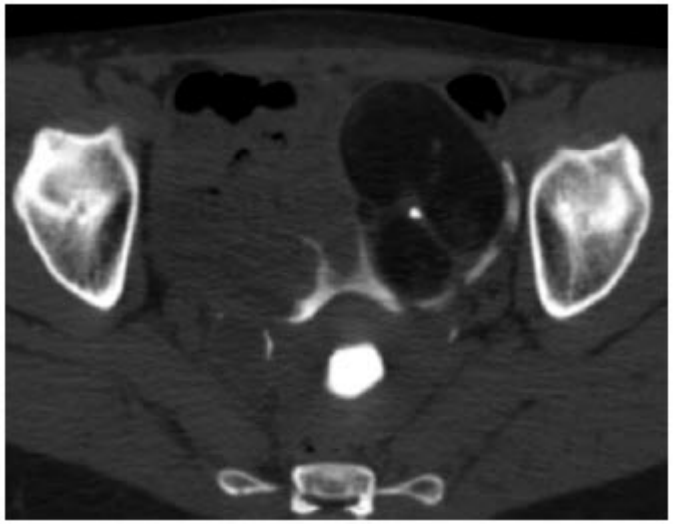

**Figure 28.** Ovarian teratoma. Axial pelvic multidetector CT image obtained at virtual hysterosalpingography shows a large left ovarian mass that contains fat tissue and calcification.

- lesões anexiais sólidas ou quística
- anormalidades intestinais
- massas pélvicas
- anormalidades ósseas

Why did you started using this method? What was the need to get started?

The HSG provides information limited to the fallopian tubes. Virtual HSG was born with the aim of providing more accurate information about the uterine cavity, cervical, uterine wall and pelvic cavity.

What is the opinion of gynecologists regarding this new method?

Gynecologists, in particular fertility specialists are very satisfied with the images and the information provided by the HSG virtual.

Where were aware of this new method?

This method was born in our department in 1999 when we try to combine a technique already established as the HSG with CT technology.

What is your experience with this new method?

We got experience with different equipment and techniques. At this point we have studied over 2000 patients with 64-row MDCT.

Do you know other hospitals in your country or abroad using this method?

The high demand for studies inspired other centers in our country to be trained in the method. We have also received fellows from other countries. In terms of publications, this year we saw a group of Turkey published their experience:

**Virtual hysterosalpingography and hysteroscopy: assessment of uterine cavity and fallopian tubes using 64-detector computed tomography data sets**

*Fertility and Sterility, Volume 93, Issue 7, 1 May 2010, Pages 2383-2384*

Onder Celik, H. Muammer Karakas, Seyma Hascalik, M. Emin Tagluk

FERTILITY AND STERILITY

The Official Journal of the American Society for Reproductive Medicine

**Virtual hysterosalpingography and hysteroscopy: assessment of uterine cavity and fallopian tubes using 64-detector computed tomography data sets**

Onder Celik, M.D.[a], H. Muammer Karakas, M.D.[b], Seyma Hascalik, M.D.[a], M. Emin Tagluk, Ph.D.[c]

Received 4 December 2008; received in revised form 12 March 2009; accepted 8 May 2009. published online 25 June 2009.

Hysterosalpingography is the primary technique in providing coarse information on the morphology of endometrial cavity and fallopian tubes. In this preliminary study, 64-detector computed tomography was used for three-dimensional imaging of endometrium and fallopian tubes.

We do not use the antibiotic in conventional HSG? Do you usually use it in conventional HSG?

We do not use routine antibiotic prophylaxis.

We use a pozzy tweezer to make traction cervix uterus. Which critical you point to our method?

In the virtual HSG is not necessary to pull the uterus, therefore avoid the use of tweezer. This approach is less traumatic and avoids complications due to bleeding.

What are your results? In what situations is that they think you have found major benefits?

The main indication is infertility. This method achieves a comprehensive evaluation of the uterus and fallopian tubes and some additional information. You can avoid the use of MRI in cases of malformation, or an sonohysterosalpingography in cases of endoluminal lesions in the uterine cavity.

Javier Vallejos

PD: congratulations for 7-0!

# CONCLUSÕES / "TAKE HOME POINTS"

- menos complicacões

- menos doloroso, mais confortável e mais fácil

- estudo mais detalhado e rigorso do sistema reprodutor feminino num só exame

- capacidade de diferenciar útero septado de útero bicórneo, sem necessidade de conjugar informação da HSG convencional com ecografia pélvica ou RMN

- capacidade de diagnosticar leiomiomas subserosos e intramurais

- melhor detalhe anatómico das trompas com algoritmo MIP e possibilidade de navegação endoscópica virtual

- possibilidade de estudo de estruturas anatómicas extra-uterinas e de detectar patologia extra-uterina acidentalmente

accurate evaluation of tubal patency. However, the resultant exposure of the patient to ionizing radiation is a relative disadvantage that must be weighed against the clinical purpose. In cases

scanning technique. In future, this test may replace the current standard, hysterosalpingog-raphy. In comparison with that method and with